

# Accepting imperfections and managing unilateral posterior crossbites in denture case

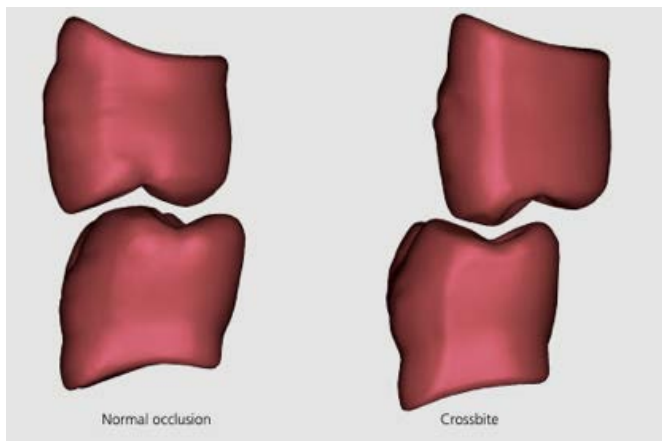
Rizwaan Chaudhry discusses the importance of accepting subtle imperfections to get a positive final result



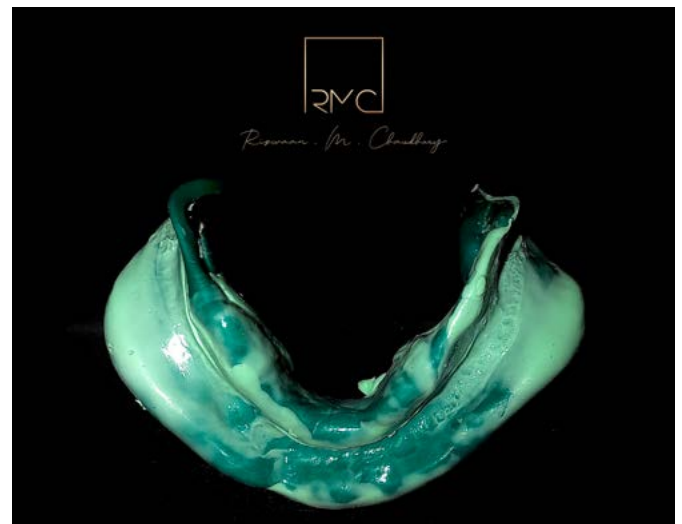
**Rizwaan Chaudhry** has a keen interest in restorative dentistry and prosthodontics. He is passionate about prosthodontics and how natural aesthetics in dentures (acrylic and chromes) can be achieved and the importance of impression taking and different impressions on the market.

Currently he is a foundation dentist based in Hull, in a practice that has its own in-built lab.

He is a keen advocate on dentists being able to produce their own dentures and the advantages of having such skill.



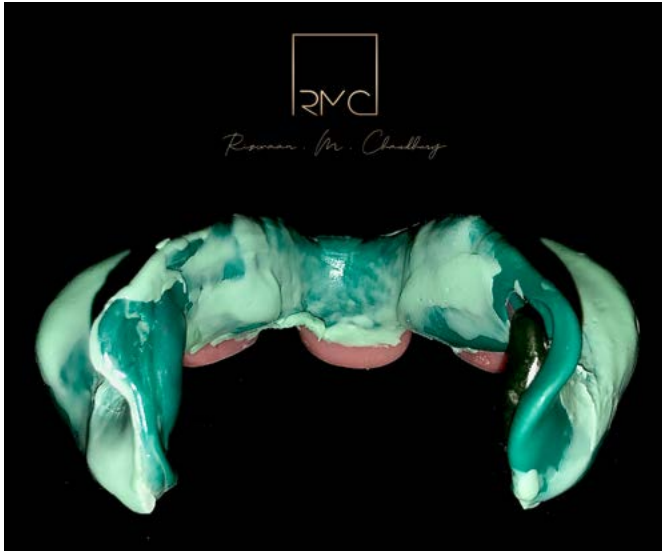**Figure 1:** Differentiation between normal occlusion and crossbite occlusion



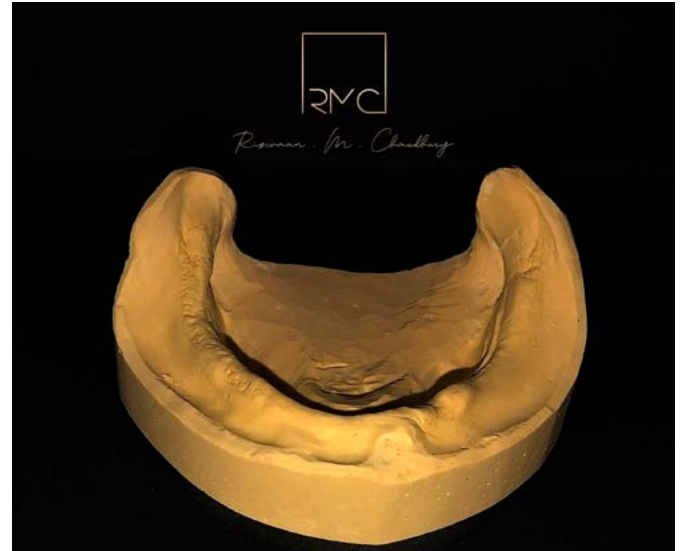**Figure 2:** Occlusal view of a secondary impression on the special tray with PVS (heavy-bodied and light-bodied)

## What is a crossbite?

Posterior crossbite is defined as any abnormal buccal-lingual relation between opposing molars, premolars or both in centric occlusion (Kennedy and Osepchook, 2005).



**Figure 3:** Posterior view of a secondary impression on the special tray with PVS (heavy-bodied and light-bodied). Take note on the extension of the retromolar pad area



**Figure 4:** Secondary impression cast. Cast within 30 minutes of impression taking

A unilateral presentation with a functional shift of the mandible towards the crossbite is the most common form of posterior crossbite. It occurs in around 97% of posterior crossbites (Thilander and Lennartsson, 2002).

A unilateral posterior crossbite can sometimes present with a mandibular midline discrepancy (Sudhakar and Dinesh, 2013). Possible aetiology can consist of either dental, skeletal or neuromuscular functional components (Kennedy and Osepchok, 2005).

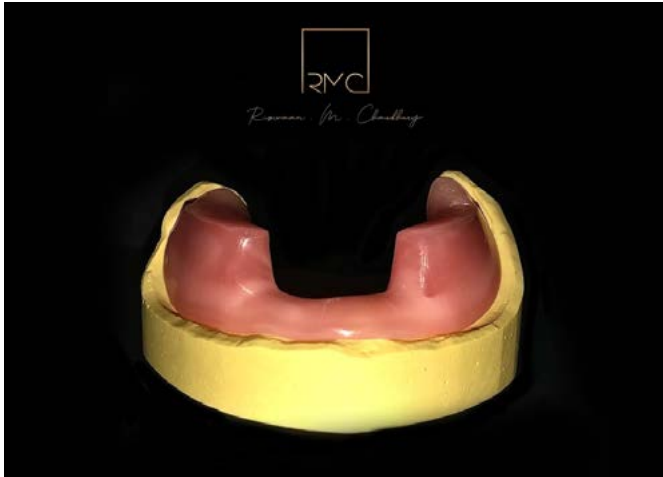When a crossbite is detected we class this as class III: mesio-occlusion. The pattern shown involves the buccal cusp of the upper molar, occluding with the central fossa of the lower molar.

The majority of studies have discussed treatments in children, but fewer studies assess treatment options within adults, especially those who are edentate and require some form of dentures to allow masticatory efficiency (Tsarapatsani et al, 1999).

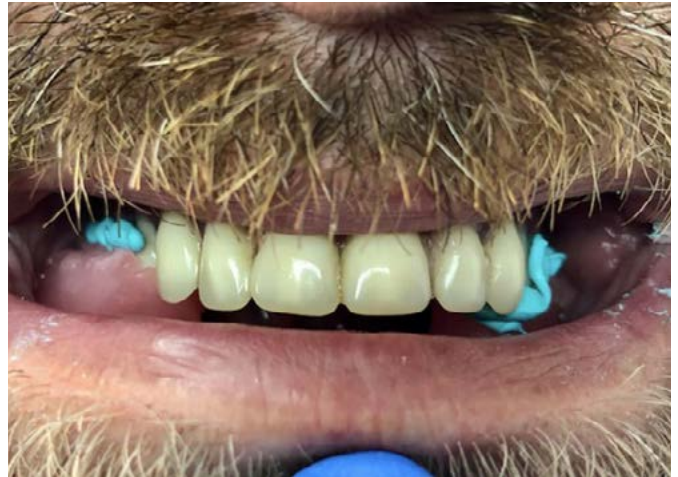The following clinical case describes the management of a unilateral crossbite with the provision of a lower complete acrylic denture and acceptance of compromised aesthetics.

## Case presentation

A 46-year-old male was transferred over to me by an associate dentist due to a repeated lower broken denture.



**Figure 5:** Lower Manchester block



**Figure 6:** Bite registration taken on a Lower Manchester block in RCP with blue mousse

The patient just had an upper complete acrylic denture, with no lower to present due to repeated fractures. As such it was decided to provision a new lower complete denture, which would be reinforced.

### Clinical examination

A thorough intraoral and extraoral examination was carried out during the initial appointment.

Both the maxillary and mandibular ridge were well defined and healthy. The upper complete denture had good retention and stability. The patient was happy with the upper denture and had no complaints to present.

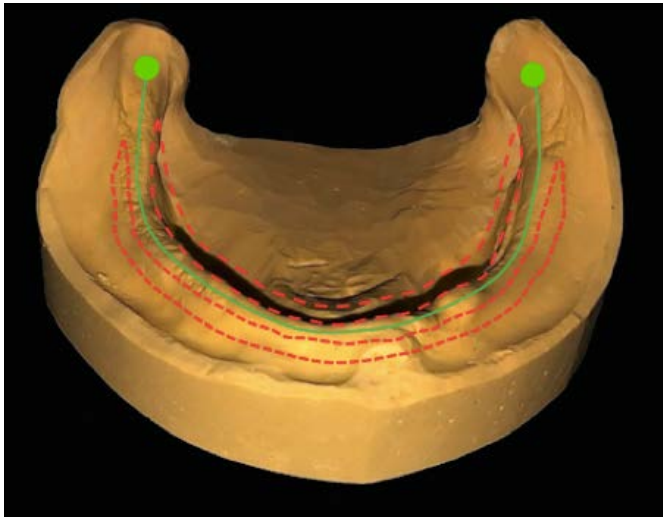
It was the patient's wishes to have the lower denture reinforced due to repeated fractures. On questioning, the patient highlighted the denture kept fracturing around the lower right canine.

The lower ridge had sufficient ridge with early signs of resorption.

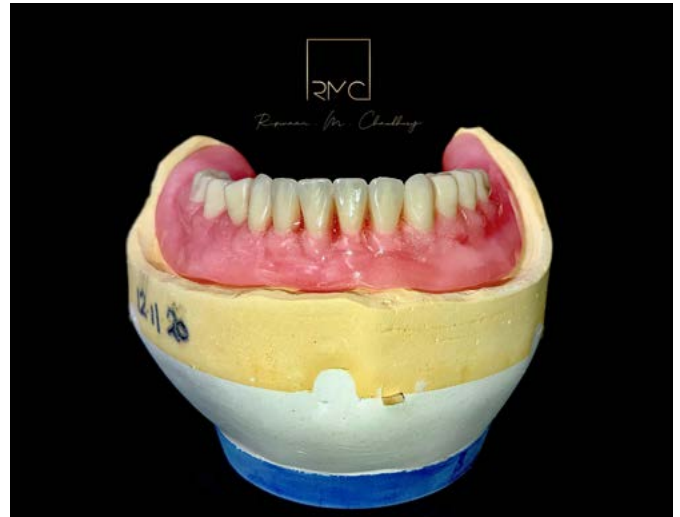### Primary and secondary impressions

Upper and lower primary impressions were taken. For the upper an impression was taken of the upper complete denture. While for the lower a medium-sized stock tray was selected where the green stick was applied on the retromolar pads, lingual and labial sulci.

Alginate was loaded on to the tray and placed in the mouth where border moulding was conducted.



**Figure 7:** Indication of the neutral zone. The green line where the teeth will be placed. Red areas where the neutral zone will be violated if the teeth are positioned in this area



**Figure 8:** Lower composite wax try in

I constructed the lower special tray, which had three stubbed handles (two located on the right and left of the posterior region and one in the central region). Furthermore, the tray was close-fitting with no perforations and extended around the retromolar pads.

The tray was trimmed two mm short of sulcus depth for adequate border moulding.

Polyvinyl Siloxane (PVS) was selected as the impression material of choice. And the secondary impression was done via a two-stage technique.

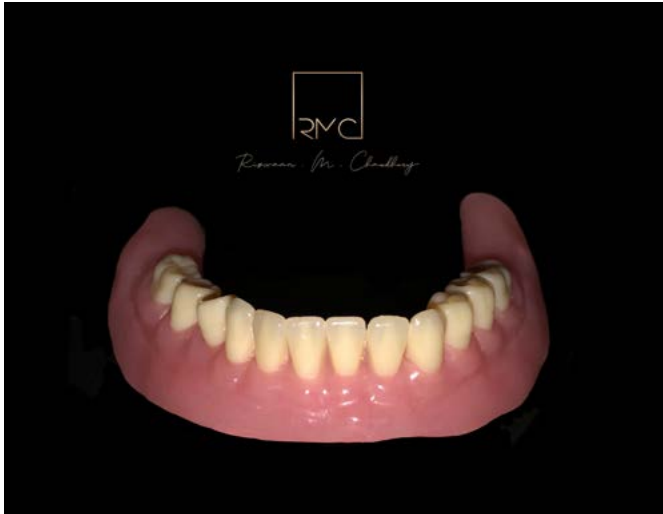First, the green stick was applied around the retromolar pads, lingual and labial area. The tray was loaded with PVS heavy-bodied, while PVS light-bodied was applied onto the ridge in the mouth and around the lingual and labial sulcus.

The tray was inserted and border moulded with relative tongue movements ensuring lingual sulcus was captured in function.

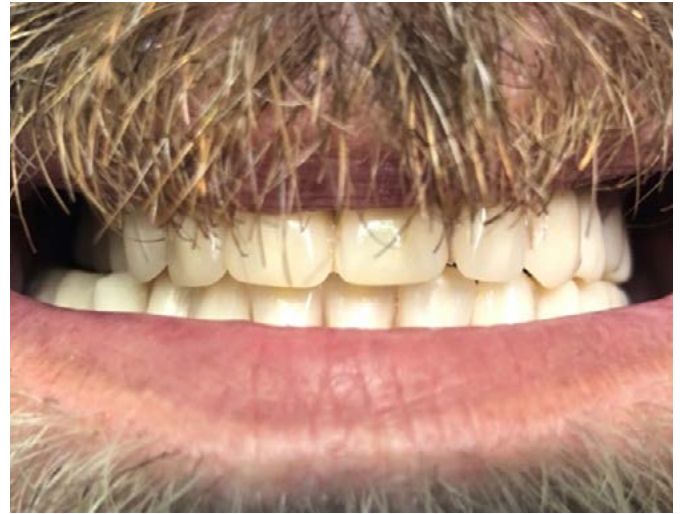Extra care was taken to ensure sufficient green stick was applied around the retromolar pads. This would allow me to capture the area well, which would aid in denture retention and stability (as noted in Figure 3).

### Bite registration stage

I have always advocated a lower Manchester block compared to the traditional bite block due to several reasons:



**Figure 9:** Lower composite wax try in, left-hand side view



**Figure 10:** Intra-oral try in of lower wax denture

1. Allows the clinician to check extensions around the peripheral areas
2. Due to the blocks being positioned in the posterior section on both sides. It allows more accurate control over the OVD
3. Can easily assess if RCP is achieved
4. Patient-friendly, which doesn't feel like a mouthful of wax.

The lower Manchester block was inserted into the mouth and occlusal height reduced appropriately as needed ensuring FWS (freeway space) between 3-4mm.

Once I was satisfied with the occlusal height, the blue mousse was injected onto the occlusal surfaces of the blocks and bite recorded in RCP (retruded contact position).

It was at this stage I had suspected possible crossbite on the right-hand side.

### **Fabrication of a lower try-in**

The bite reg was articulated via an Artex CN (average-value). It was at this stage where I confirmed the patient had bilateral cross-bite on the right-hand side.

When I was training as a dental technician, there was one rule for the lower which we technicians had to follow. That is teeth on the lower ridge have to be on the ridge.

As a dental student, I was then educated on reasoning. Teeth are placed on the lower ridge as it's a zone of minimal conflict ie the neutral zone.

Now the question should be asked why is the neutral zone important, especially with regards to a lower complete denture?

The neutral zone is an area between the tongue (on one side) and the cheeks/lips (the other side) where the muscular displacing forces acting on the denture are least.

With this in mind if the teeth were set too far lingually then during tongue movement it would displace the denture. If the teeth are set too far buccally, which can displace the lips and cheeks, then during muscle movements it will lead to dislodgement of the denture.

The other area I had to contend with was regarding the mould of the teeth that are to be selected.

If I went ahead with moulds that had prominent and well-defined cusps then during lateral movements there would be conflict leading to the displacement of the lower denture. Furthermore, it would not allow the dentures to occlude in harmony.

With this in mind, I had decided to go ahead with moulds that detailed flat cusps. This way it will allow lateral movements without disruption of the lower denture (ie balanced articulation), keeping the lower denture in contact with the upper during protrusive movements, maintain canine guidance and allow for balanced occlusion (ie teeth meeting evenly on both sides).

Furthermore, it would lead to minimal modification on the acrylic teeth.

Finally, to accommodate natural aesthetics the lower midline shift was moved slightly to the right-hand side.

## **Try-in stage**

They were no complaints during the try-in stage. Lateral guidance, protrusive movement, as well as retention, stability and occlusion were all assessed.

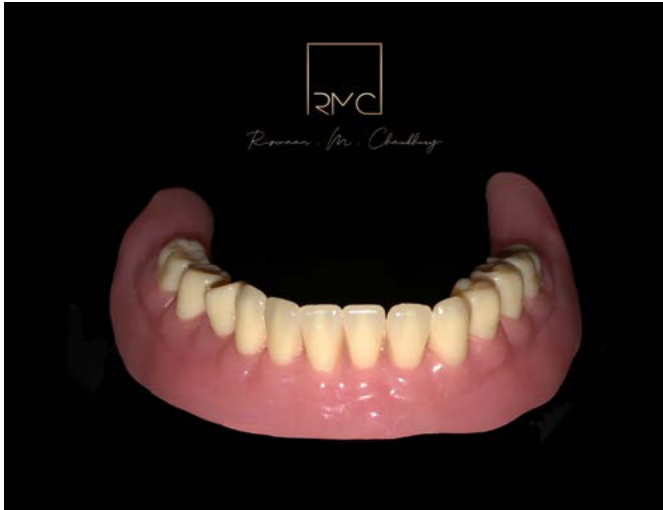It was here where I discussed with the patient about the crossbite on the right-hand side and explained its relevance.

I further highlighted to the patient because his previous lower denture did not accommodate the cross-bite it could have been the reason for persistence fracture.

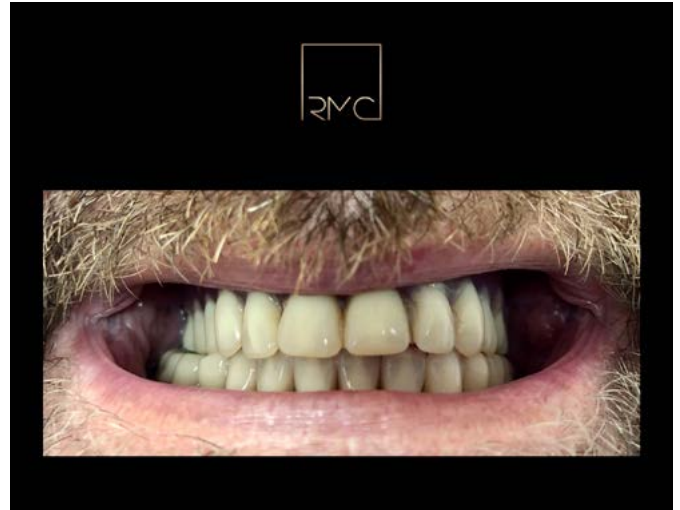## **Fit**

No modifications were needed at the fit stage.

The patient was able to tolerate the lower denture well which helps well within the mouth.



**Figure 11:** Lower complete acrylic denture (note the extension around the retro-molar pads)



**Figure 12:** Four-week review intra-oral photo

I highlighted the extension around the retro-molar pads, which will aid in retention and stability and this will take time to get used to, which the patient understood and was happy with.

### Review

No complaints to present. The patient has been managing well with the denture and is extremely happy.

The patient did highlight that it took a while to get used to the denture due to the extension around the retro-molar pads, however, this has settled.

The patient has been managing to eat well and has further highlighted that they are retained in the mouth extremely well and can eat more solid foods.

### Significance of case

Initially, when you looked at the try-in photograph you would have noticed a couple of points:

1. The centre lines do not match
  2. The right side (patients right) is not interdigitating with the upper.
- So with this in mind would you say that the try in constructed is incorrect?

The main point I wanted to highlight with this case was that sometimes imperfections in dentistry can go a long way, especially in the field of prosthodontics.

However, subtle changes such as changing the moulds of the teeth, moving the centre line can have a positive impact on cases.

To ensure a positive outcome each stage had to be thought out starting from the primary impression, to bite registration stage, to try-in and finally fit.

I am extremely lucky that I was able to fabricate the denture myself. Hence, this allowed me to set the denture up in a way that would function well.

Yes, aesthetics is important. But as is functionality and natural harmony of the appliance.

It might not be perfect to look at but if it can function without causing trauma then surely the needs of the patients have been met?

For a list of references contact [seb.evans@fmc.co.uk](mailto:seb.evans@fmc.co.uk).